

## Osteogenesis Imperfecta: An Overview

Rahma Ira Mustikasari<sup>1\*</sup>, Nur Rochmah<sup>1</sup>,  
Muhammad Faizi<sup>1</sup>, Qurrota Ayuni Novia Putri<sup>2</sup>

<sup>1</sup>Faculty of Medicine, Department of Child Health, Dr. Soetomo General Hospital,  
Airlangga University, Surabaya, East Java, Indonesia

<sup>2</sup>Faculty of Medicine, Airlangga University, Surabaya, East Java, Indonesia

E-mail: [rahma.a.mustikasari-2017@fk.unair.ac.id](mailto:rahma.a.mustikasari-2017@fk.unair.ac.id); [nur-r@fk.unair.ac.id](mailto:nur-r@fk.unair.ac.id);  
[muhammad.faizi@fk.unair.ac.id](mailto:muhammad.faizi@fk.unair.ac.id); [qurrotaanp@gmail.com](mailto:qurrotaanp@gmail.com)

\*Corresponding author details: Rahma Ira Mustikasari;  
[rahma.a.mustikasari-2017@fk.unair.ac.id](mailto:rahma.a.mustikasari-2017@fk.unair.ac.id)

### ABSTRACT

Osteogenesis Imperfecta (OI) or commonly referred to as brittle bone disease is a congenital connective tissue formation disorder characterized by bone fragility, osteopenia, skin disorders, blue sclera, dentinogenesis imperfecta (DI), and hearing loss. The diagnosis of Osteogenesis Imperfecta is based on history, clinical examination, lumbar bone density, bone biochemistry and radiographic findings. Diagnosis of osteogenesis imperfecta can be difficult and some primary skeletal disorders can be mixed with osteogenesis imperfecta. Management of OI requires a multidisciplinary approach such as endocrinologists, pediatricians, orthopedic surgeons, dentists, medical rehabilitation specialists, geneticists, psychologists, and occupational therapists. Bisphosphonate therapy has been shown to be effective in reducing pain, fracture frequency, and disability. Medical services such as bisphosphonate treatment and rehabilitation in individuals with OI have the long-term goal of optimizing the health and well-being of bone fragility and deformity.

**Keywords:** Osteogenesis Imperfecta (OI), multidisciplinary approach, bisphosphonate therapy

### INTRODUCTION

Osteogenesis Imperfecta (OI) or commonly referred to as brittle bone disease is a congenital connective tissue formation disorder characterized by bone fragility, osteopenia, skin disorders, blue sclera, dentinogenesis imperfecta (DI), and hearing loss [1,2]. Osteogenesis imperfecta is known as an autosomal dominant disorder caused by mutations in COL1A1 and COL1A2, coding for type I collagen chains 1 (I) and 2 (I), which are the most abundant proteins in bone, skin, and tendon extracellular matrix [2]. The prevalence of OI is reported to be 4.0–6.7 per 100,000 live births. Based on all patients registered with a diagnosis of OI in the Danish National Patient Register (NPR) 1977–2013, Folkestad et al., have estimated the incidence of OI in Denmark to be 15 (range 5–24) per 100,000 births. The prevalence of OI population in Denmark is 10.3 per 100,000, with 575 patients enrolled with a diagnosis of OI at NPR and living at the end of 2012 and a total population of 5,602,628 people at the end of 2012[4].

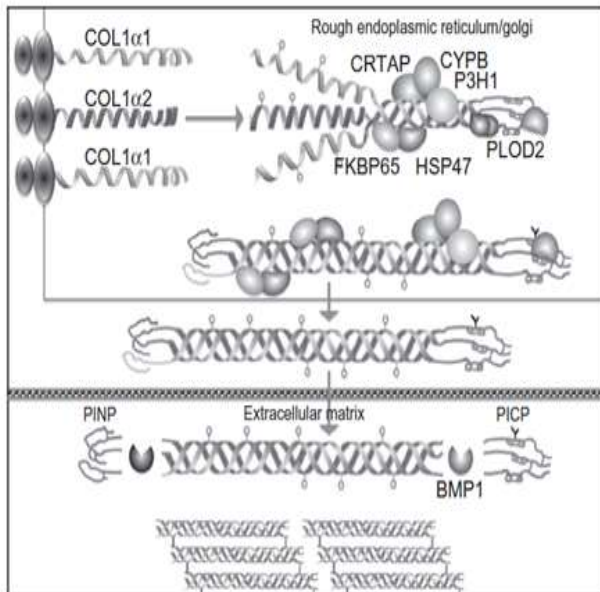
However, over the last few years, a number of other genes have been identified that are involved in the development of OI. The degree of bone fragility in OI has a broad spectrum, from asymptomatic individuals with mild manifestations to fractures and perinatal lethality. Osteogenesis Imperfecta is largely due to a dominant mutation in COL1A1 or COL1A2, which affects the synthesis and structure of the alpha 1 or alpha 2 chain of type I procollagen [5].

OI treatment is still unclear, it takes a multidisciplinary approach to OI management. Management of OI requires a multidisciplinary approach such as endocrinologists, pediatricians, orthopedic surgeons, dentists, medical rehabilitation specialists, geneticists, psychologists, and occupational therapists. There is also bisphosphonate therapy which has been shown to be effective in reducing pain, fracture frequency, and disability. Bisphosphonates (BP) are the pharmacological treatment of choice in OI because they reduce the efficiency of osteoclasts and cells that break down bone, thereby reducing bone resorption. This treatment causes the cortex to become thicker, thereby reducing long bone fractures, increasing bone mineral density (BMD) and reducing pain [6,7]. Medical services such as bisphosphonate treatment and rehabilitation of individuals with OI have a long-term goal of optimizing health and well-being from bone fragility and deformity.

### ETIOLOGY

Mutations in the COL1A1 and COL1A2 genes account for about 90 percent of all cases of osteogenesis imperfecta. This gene provides instructions for making the protein used to assemble type I collagen, which is the most abundant protein in bone, skin, and other tissues that provide structure and strength to the body (connective tissue). Most of the mutations that cause type I OI occur in the COL1A1 gene. This mutation reduces the amount of type I collagen produced in the body, which causes bones to become brittle and break easily.

The mutations involved for OI types II, III, and IV can occur in the COL1A1 or COL1A2 genes. These mutations usually alter the molecular structure of type I collagen. Abnormalities in the structure of type I collagen weaken the connective tissue, especially bone, resulting in the characteristic features of OI with bone fragility [8]. The mechanical strength of connective tissue is mainly due to the fibrils that form the template for matrix deposition. In bone, the fibrils are the template for mineralization, that is, in this case, for the incorporation of hydroxyapatite crystals. The mechanical properties of bone depend on the intimate relationship between collagen fibrils and hydroxyapatite crystals [9]. Most cases of OI have heterozygous mutations in type I collagen and an autosomal dominant inheritance. In about 10% of cases of OI with mutations in type I collagen and in which the parents are not involved, OI is the result of parental mosaicism [10].



**FIGURE 1:** Collagen associated with the metabolism of mutated genes in OI. The majority of mutations that give rise to autosomal dominant OI can be traced to the type I collagen procollagen genes COL1A1 and COL1A2. Additional proteins found to be mutated in the form of autosomal recessive OI include FK506 binding protein 65 (FKBP65), heat shock protein 47 (HSP47), cartilage associated protein (CRTAP), prolyl 3-hydroxylase 1 (P3H1), cyclophilin B (CYPB), procollagen telopeptide lysyl hydroxylase 2 (PLOD2), and bone morphogenetic protein 1 (BMP1) [11].

A number of genes encoding proteins involved in collagen processing have been identified as causative factors for the autosomal recessive form of OI when mutated. The complex molecule consists of cartilage-associated protein (CRTAP, encoded by CRTAP), prolyl 3-hydroxylase 1 (P3H1, encoded by LEPRE1) and cyclophilin B (CYPB, encoded by PPIB). Mutations by CRTAP, LEPRE1 and PPIB were identified to cause cases of autosomal recessive OI. Mutations in other procollagen chaperon complexes encoded by FKBP10 (FK506 binding protein 65) and SERPINH1 (heat shock protein 47) also cause recessive OI. Mutations in the telopeptide lysyl hydroxylase encoded by PLOD2 are also associated with recessive OI. A mutation in BMP1, a carboxy-terminal propeptidase, has also been associated with recessive OI. A mutation in the major transcription factor in osteoblast differentiation, Osterix (OSX or SP7), is associated with OI. Mutations in the SERPINF1 gene encoding the pigment-derived epithelial factor (PEDF) are also associated with recessive OI [11].

Citations are included in several journals that discuss the etiology of gene mutations other than collagen.

**DIAGNOSIS**

Initial diagnosis is largely based on clinical and radiographic findings. Fractures from minor trauma, long bone curvature deformity, and growth deficiency are characteristic features, which are common to all types of OI but other skeletal features may be present. Other skeletal features include macrocephaly, flat midface and characteristic triangular face, dentinogenesis imperfecta, chest wall deformities such as pectus excavatum or carinatum, barrel chest, and scoliosis or kyphosis depending on age and severity. The diagnosis of Osteogenesis Imperfecta is based on history, clinical examination, lumbar bone density, bone biochemistry and radiographic findings. Metabolic causes of osteoporosis are important to exclude early on. The most general description of each type of OI will be described according to the clinical classification proposed by Van Dijk and Sillence [12,3]. Bone radiographs show generalized osteopenia, and some combination of crooked long bones, narrowed tubules, and metaphyseal widening, thinning and flattened ribs, narrowing of the chest apex, and vertebral compression [3]. Dual Energy X-Ray Absorptiometry (DXA) examination for bone density is very useful, which is usually low, but not specific for diagnosing OI [3,13].

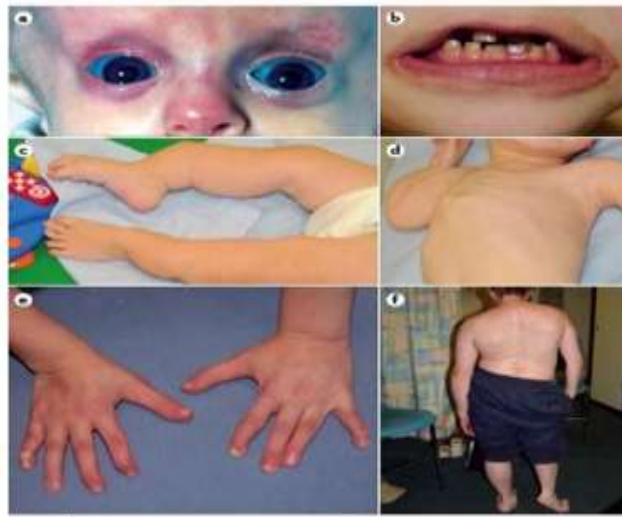
Practice guidelines for the laboratory diagnosis of OI published in 2012 by the European Molecular Genetics Quality Network working group revealed that patients with suspected OI should be subjected to sequence analysis and quantitative analysis of the COL1A1 and COL1A2 genes in genomic DNA [4]. Genetic testing can help confirm the diagnosis. However, given that more than 1500 dominant mutations in COL1A1 or COL1A2 have been identified to date, genetic sequencing of peripheral blood or cultured fibroblasts is required [13]. This molecular diagnosis is very useful for counseling on prognosis, recurrence, and heritability, and for variable response to drugs [3].

**CLASSIFICATION**

In 2009 the International Nomenclature Group for Constitutional Disorders ICHG of the Skeleton (INCDS) classified OI into 5 groups based on their phenotype. The division of OI according to the INCDS uses Roman nomenclature for identification and uses Arabic nomenclature to indicate phenotypes [14].

**TABLE 1:** The International Nomenclature Group for Constitutional Disorders ICGH of the Skeleton 2009.

OI Classification	Phenotype
1/I	Mild, does not cause deformity
2/II	Severe, presenting as a lethal perinatal abnormality
3/III, VI, VIII, IX, X, type 1 Bruck syndrome	Moderate-severe, causing progressive deformity
4/IV, IV, VII, XI, XII, XIII	Moderate
5/V, osteoporosis-pseudoglioma syndrome, idiopathic juvenile osteoporosis, Bruck syndrome type 1 and type 2	Moderate, interosseous membrane calcification

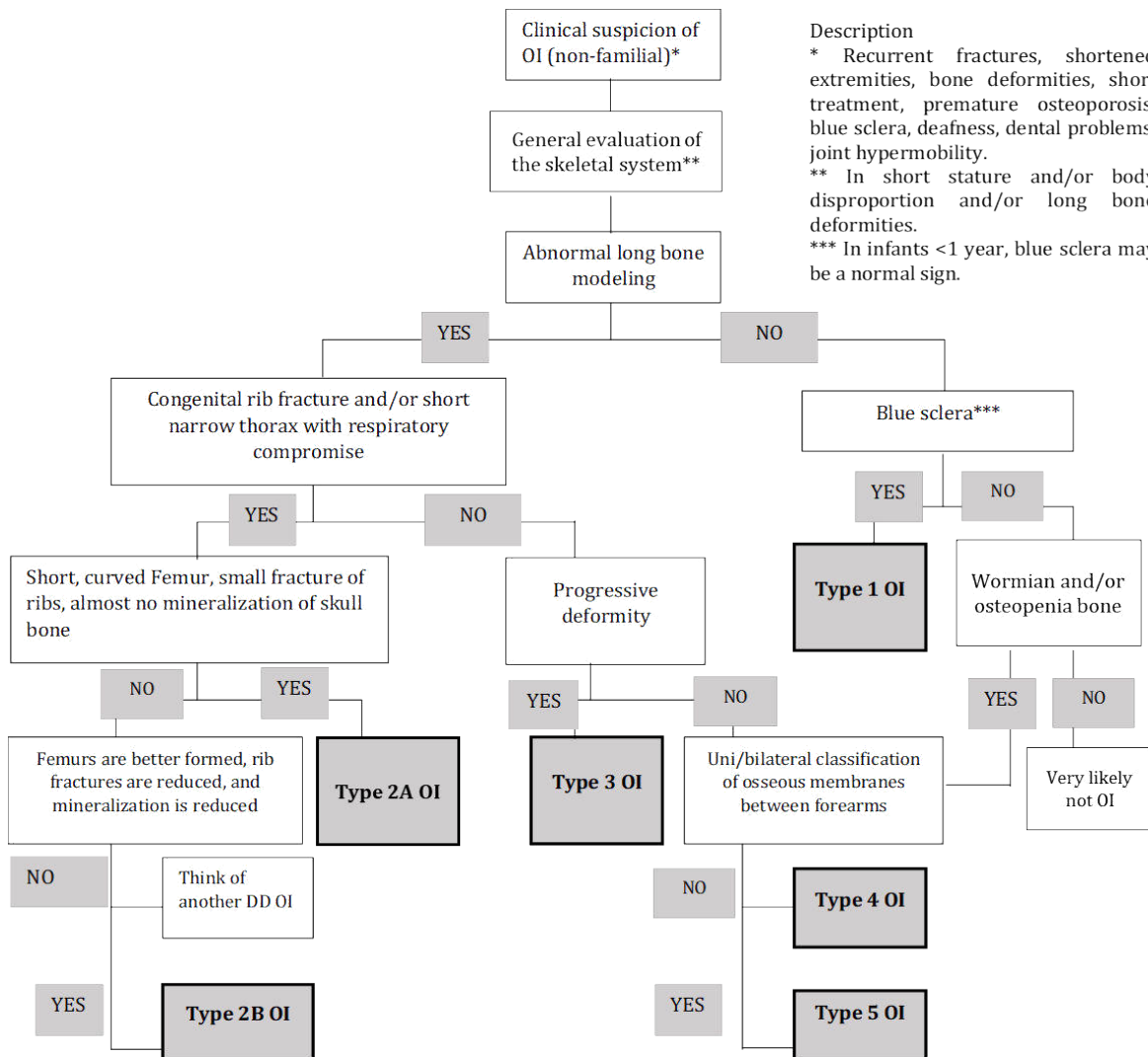


**FIGURE 2:** Clinical features associated with OI. Patients with OI may present with secondary features: blue sclera (part a); DI (section b) is characterized by dental dysplasia, which makes teeth discolored and porous; limb deformity (section c); pectus carinatum chest deformity (section d; known as pigeon's chest); clinodactyly (section e) is characterized by abnormal curvature of the fingers; and scoliosis (section f), as indicated by spinal curvature [15]

**Type I Osteogenesis Imperfecta**

Type I OI is the most common and mildest form, and is characterized by distinctive blue sclera that persist into adulthood [5]. Patients with this type of OI usually have no major bone abnormalities and significant variability in the number of fractures, even within the same family. Growth and stature are usually slightly delayed in type I OI. Fractures usually begin when the child begins to mobilize [16]. A small proportion of infants with type I OI have a form of femoral bowing at birth.

The first fracture can occur at birth or during a diaper change. The first fracture occurs when the baby starts to walk and falls [20]. Recurrent fractures can occur and can lead to significant and permanent disability if optimal orthopedic and medical management is not performed. Plain radiographs are often normal [18,5]. Joint hypermobility may occur and may increase the risk of premature joint degeneration with resultant osteoarthritis and chronic joint pain. There may also be a tendency to progress to scoliosis and chronic back pain [19].



**Description**  
 \* Recurrent fractures, shortened extremities, bone deformities, short treatment, premature osteoporosis, blue sclera, deafness, dental problems, joint hypermobility.  
 \*\* In short stature and/or body disproportion and/or long bone deformities.  
 \*\*\* In infants <1 year, blue sclera may be a normal sign.

**FIGURE 3 :** Flowchart of Clinical Diagnosis of Osteogenesis Imperfecta [17].

### Type II Osteogenesis Imperfecta

It has historically been described as perinatal lethal, it is associated with pulmonary failure with involvement of severe chest cavity abnormalities with small volumes, deformities, and recurrent rib fractures. Patients with this type of OI are often diagnosed at the time of prenatal ultrasound examination, which includes long curved bones with several fractures and low body weight and length compared to gestational age. The sclera is usually dark blue in color and the connective tissue is very fragile. The skull is large and soft to the touch due to its low mineral content, historically referred to as the "ping-pong ball" skull. The anterior fontanelle is large and usually extends to the metopic ridge. Callus formation on the ribs can be palpated. Extremities that are short, curved, or deformed. The hips are usually flexed and abducted in a "frog leg" position [16,18].

### Type III Osteogenesis Imperfecta

This is the most severe type of OI but can survive into adulthood. It is usually diagnosed at birth, i.e. it is easy to fracture bones when handling the baby. Death can occur early in life (weeks or months) if there is a rib fracture resulting in lung organ failure. This type is also known as the "Progressive Deforming Type" because many individuals have more than 200 fractures and experience deformity even without a fracture. This defect can reach 70-90% in long bones, caused by mechanics by muscle/tendon or angulation from previous fractures [18]. Osteogenesis Imperfecta types II and III are usually difficult to distinguish in addition to the occurrence of multiple bone fractures. CXR OI type III in neonates does not describe "crumpled long bone" and OI type II does not describe the presence of "beaded rib" so the difference between the two types is based on respiratory status [13].

### Type IV Osteogenesis Imperfecta

Classification of type IV OI includes children with a phenotype that does not match Sillence type I or III. Children with this type are characterized by multiple fractures with varying degrees of deformity, as well as many variations in scleral color, cranial settling, dentinogenesis imperfecta, and stature. Many of these children, previously classified as type IV with a known recessive form, are now recognized as having the same features as the uncommon form [16]. Osteogenesis Imperfecta type IV is characterized by bone fragility without the typical features of the type I phenotype (ie blue sclera and deafness). Fractures can occur at any age and most of these patients are of short stature. A small proportion have severe and progressive lower extremity deformity rather than repeated fractures. Dentinogenesis imperfecta varies but when symptoms are present it can be associated with a greater frequency of fractures. Autosomal dominance is inherited from mutations in COL1A1 and COL1A2 [5]. Body stature varies and can vary greatly within families. Basilar compression can occur [18].

### Type V Osteogenesis Imperfecta

Type V is the first non-collagen type OI to be identified and is a mutation of the IFITM5 gene that has been shown to cause an autosomal dominant form of OI. Classically, patients have a characteristic phenotype with moderate to severe bone fragility, although family studies have shown a variable phenotype. Body stature varies and can vary greatly within families. Dentinogenesis imperfecta is common but may be mild. The sclera is usually light blue or gray at birth but quickly changes to near normal. Hearing loss is sometimes present and basilar compression may occur [5,16,19].

### Type VI Osteogenesis Imperfecta

Osteogenesis Imperfecta type VI has a moderate to severe phenotype associated with frequent but indistinguishable fractures from type IV OI. The hallmark of this type is abnormal bone mineralization on histologic examination [20]. Osteogenesis Imperfecta type VI is difficult to distinguish in the absence of bone histology, which is characterized by the absence of a birefringent form in the normal lamellar bone under polarized light, a frequent fish-scale appearance, and high levels of unmineralized osteoid without increased remodeling. In addition to the fish-scale pattern, bone histomorphometry showed marked osteomalacia (in the absence of rickets), and unsurprisingly a "looser zone" (radiographic signs of bone fragility) in the scapula, ribs, and long bones. There is evidence that there is a response to bisphosphonate therapy, especially an increase in mobility scores and a decrease in fracture incidence compared to other types of OI [21,5].

### Types VII, VIII and IX Osteogenesis Imperfecta

Osteogenesis Imperfecta types VII and VIII are distinguished by an autosomal recessive inheritance. Post-translational hydroxylation dysregulation of the proline residue at position 986 of COL1A1 has been implicated in the pathogenesis of type OI. \*The clinical features of these two subtypes depend on the remaining functional protein and overlap in clinical severity with type II and type III OI. There are several clinical indicators that suggest a diagnosis in the spectrum of moderately severe OI, so it may be difficult to distinguish these subtypes. Infants tend to have congenital bone fractures and significant undermineralization of bone. The "popcorn" epiphyses are thought to be the result of abnormal hydroxylation of type I collagen in cartilage. This finding is not pathognomonic for type OI as has been seen in families with type III OI. Perhaps when people with overt type III OI and popcorn epiphyses mutation analysis were obtained on CRTAP or LEPRE1 they were said to have no type III OI. Individuals with recessive OI tend to be short and rhizomelic in stature with a white vara coxa and sclera. The population initially identified for the presence of a CRTAP or LEPRE1 mutation was the African, African-American and Irish tourist population, but other ethnicities were also represented. It is not clear what percentage of OIs are caused by CRTAP or LEPRE1 mutations [18].

Osteogenesis Imperfecta type VII is a rare autosomal recessive condition described in the First Nations community in northern Quebec. It is caused by mutations in CRTAP and is associated with a moderate to severe phenotype involving birth fractures, bluish sclera, early lower limb deformity, coxa vara, and osteopenia. Rhizomelia (proximal limb disproportion) is a prominent clinical feature that differentiates the type of OI. LEPRE1 (OI type VIII) and PPIB (OI type IX) are involved in the triple helix folding of type 1 collagen and produce a severe phenotype with autosomal recessive inheritance. Of particular note, the FKBP10 mutation has been associated with a significant pelvic abnormality (protrusio acetabuli). Although the list of causative genes and subtypes of OI has expanded over the past few years, there have been recent steps to reduce the classification of five different subtypes based on phenotype alone [5].

### DIFFERENTIAL DIAGNOSIS

Differential diagnostic questions arise over successive developmental periods, for which type of OI should be considered over other bone conditions. Diagnosis of osteogenesis imperfecta can be difficult and some primary skeletal disorders can be mixed with osteogenesis imperfecta.



Exclusion of idiopathic or juvenile osteoporosis may be a challenge. Children with mild bone fragility and no skeletal-additional features of osteogenesis imperfecta, and children with fractures at birth may also demand careful assessment. Some cases of OI types I and IV may be misdiagnosed as child abuse. Child abuse is a major cause of fractures, and the highest incidence is in the first year of life. The most common signs are rib fractures, and classic metaphyseal lesions of the femur. Decreased bone density, wormian bones, dentinogenesis imperfecta, and bent long bones can help in the differential diagnosis. Blue sclerae are not helpful in a time when many normal children also have a tinge of scleral blue. Children with OI generally do not have bruising at the fracture site. A rapid molecular diagnosis can be confirmed when the differences are subtle [12,21].

### MANAGEMENT

Clinical management of OI requires a multidisciplinary approach involving pediatricians, endocrinologists (bone and mineralogynologists), rehabilitation specialists, orthopedic surgeons, dentists, geneticists, social workers/psychologists, physiotherapists, and occupational therapists. This list of healthcare professionals is not exhaustive and highlights the multidisciplinary approach needed for optimal management of children with OI. The goal of OI management is to maximize motor function and therefore improve functional outcome. The level of intervention required depends on the severity of the clinical phenotype. Bisphosphonate therapy remains the mainstay of medical care in OI, the benefits of which complement the rehabilitation and management aspects of surgery. New therapies for example, the RANKL antibody, are also being explored for their use in OI [5,22].

### Rehabilitation

Physical therapy is used to guide motor skill acquisition for severely involved children and is important in maximizing weight training to prevent fractures or during recovery from fractures. The heterogeneity of the patient population requires a multidisciplinary approach to setting goals and monitoring progress [22]. Treatment goals and strategies are personalized and generally aimed at motor development, strength, joint contractures, and mobility. The use of orthotics can also be useful in optimizing mobility [5]. Hydrotherapy is a useful means of gradual return to weight-bearing. Wheelchairs and walking aids are prescribed according to the child's needs, taking into account the balance between sitting mobility for practical use and weight training to maintain bone strength and the ability to assist with mobility.

A 4-year follow-up study of rehabilitation in OI showed improvement in self-care and social functioning with all types of OI but stagnant mobility rates in moderate-severe OI. The goals of rehabilitation and physical therapy may change with time as the focus shifts from acquiring motor milestones to optimizing learning in schools [5].

### Surgical Treatment

Fractures are the most common reason children with OI see a surgeon. Fracture healing time for children with normal OI even with bisphosphonate therapy. Excessive immobilization should be avoided during fracture treatment as it can lead to weakness, muscle stiffness and secondary bone osteopenia, which can lead to more fractures. The best treatment for bone fractures in infants is a simple form of immobilization with the aim of providing comfort to the limb when the initial fracture callus is formed. Fractures heal quickly in infants (2-3 weeks). Toddlers and children vary in the number of fractures experienced and in the amount of limb deformity that occurs. Leg deformity is a combination of

those resulting from fractures of healed bone, as well as gradual distortion of the shape of the bones. Some children with OI have few defects and have fracture patterns similar to those seen in the normal pediatric population. This type of bone fracture is managed with closed or open management using standard techniques. Plate fixation should be avoided if possible because there is a higher risk of subsequent periimplant fracture. There is an increased incidence of bone traction failed transverse fracture of the olecranon or patella in children with OI [22].

### Pharmacological Treatment

The decision to initiate pharmacotherapy, such as bisphosphonates, depends on the child's clinical severity (presence of long bone deformity, bone pain, frequent fractures) rather than bone mineral density or collagen mutation status [22]. There are no data directly comparing intravenous and oral bisphosphonate therapy in children with OI. In one small randomized trial comparing oral alendronate with intravenous pamidronate for children with OI, bone density increased similarly in both groups. Nonetheless, many clinicians believe that intravenous pamidronate is more effective in treating bone pain and may have a greater effect on fracture risk reduction than oral therapy [23].

### Calcium and Vitamin D Supplementation

Children with OI should be assessed to ensure that there is an adequate intake of calcium and 25-hydroxyvitamin D. One in four children with OI has evidence of vitamin D deficiency, and serum 25-hydroxyvitamin D concentrations are independently associated with bone mineral density [22]. Calcium and vitamin D intakes are based on the recommended daily dose (RDA) for a child's age (700-1300 mg/day for calcium and 400 to 600 int. vitamin D units). Children should be supplemented before bisphosphonate treatment is started if dietary intake is inadequate. Calcium homeostatic indices (eg, calcium, phosphorus, PTH) and renal function should be assessed before starting treatment and followed every 6 to 12 months. Calcium levels should also be assessed before each intravenous bisphosphonate infusion is given to ensure that the child is not hypocalcemic [22].

### BIPHOSPHONATES

Bisphosphonates (BP) as a treatment for osteoporosis has been used clinically for more than two decades and have been shown to be effective in the prevention of fractures. Several studies of bone markers and histomorphometry demonstrated the antiresorptive effect of BP. Based on its effect on osteoclast function (Oc), BP causes a decrease in bone turnover and its degree can be considered as a surrogate parameter for treatment efficacy. They enter the bone for a long time and affect bone metabolism for a long time after intake is stopped. This substance is relatively safe, but the possibility of osteonecrosis of the jaw in oncology patients with high doses of BP and atypical femoral fractures is currently believed to be caused by an overemphasis on bone remodeling although it is still a matter of debate [24].

The use of BP therapy in pediatric patients was suggested in 1998 when cyclic intravenous administration of pamidronate to children with OI resulted in decreased bone resorption, increased bone density, and decreased fracture incidence. Because the mechanism of action in children is different from that in adults and because bones in children are tissues that grow and respond bisphosphonates differ from those of adult bone, it is difficult to extrapolate adult bisphosphonate therapy regimens to pediatric patients. Two years after discontinuation of pamidronate therapy, older adolescents with OI maintained spinal mass, whereas bone mass decreased in younger adolescents.

The sustained increase in BMD after bisphosphonate therapy depends on the age of the child and the amount of regional residual bone growth. In 2007 and 2014, the Cochrane Database Systemic Review concluded that the use of bisphosphonates as standard therapy in children lacked sufficient convincing data. Although many clinical trials in pediatric patients report significant increases in BMD and reductions in pain compared with placebo with bisphosphonates, there is no conclusion that BP significantly reduces the incidence of fractures in OI, neither BP improves survival in cancer patients [25].

#### Recommendation for Bisphosphonates in Children

Many genetic disorders and childhood cases are associated with osteoporosis. Bisphosphonates have been shown to increase bone mass gain, reducing fracture rates in some forms of primary or secondary osteoporosis. Bisphosphonates are also effective in treating severe hypercalcemia caused by excessive bone resorption or increased intestinal calcium absorption. In addition, treatment with BP demonstrated reduction of existing calcifications and loss of new ectopic ossifications in several disorders associated with heterotopic calcifications. Furthermore, bisphosphonates may be useful in reducing osteolytic lesions and bone pain in patients with fibrous bone dysplasia, chronic recurrent multifocal osteomyelitis and chemotherapy-associated osteonecrosis [26].

IV bisphosphonates should be considered for use in children with severe OI (eg type III), children with vertebral compression fractures or children who have two or more long bone fractures per year. Oral bisphosphonates should only be used in patients with mild to moderate OI without a vertebral compression fracture. Therapy after BMD is not recommended in children with severe OI once their condition improves. Long-term use of low-dose bisphosphonates aims to maintain bone strength during growth. The annual dose of intravenous BP can be halved once the height-adjusted BMD z score is in the -2-0 range. The dose can be reduced further once the BMD z score > 0 and treatment is continued at this lower dose until growth stops. In children with less severe OI, bisphosphonate therapy can be discontinued during childhood without deterioration in clinical status or BMD. Once a child with OI stops growing, therapy should be discontinued and the child monitored [27].

The minimum age for intravenous zoledronic acid administration is 3 months (for those under 3 months of age, therapy is given based on the consideration of the expert team, at least 2 people). Single dose IV infusion of 0.05 mg/kg/day for 30-45 minutes (maximum dose 2 mg/infusion). The dose is given at a lower dose of 0.025 mg/kg/day for neonates or infants less than 1 year old. In the first cycle of AZ administration the patient must be hospitalized for 2 days for close monitoring of acute complications that may occur. Subsequent AZ administration is sufficient for 1 day of treatment. All patients are advised to maintain adequate oral calcium intake at a daily dose of 1200 mg along with a daily dose of vitamin D (400-800 IU) [28].

#### SUMMARY

Osteogenesis Imperfecta (OI) is an inherited disorder of connective tissue due to mutations in COL1A1 and COL1A2, which are the main protein components of the extracellular matrix of bone and skin. Several other genetic mechanisms are said to play a role in the development of OI. OI management requires a multidisciplinary approach so that early diagnosis in OI is important. There is no cure for OI and therapy is largely supportive. Medical services such as bisphosphonate treatment and rehabilitation in

individuals with OI have the long-term goal of optimizing the health and well-being of bone fragility and deformity.

#### ACKNOWLEDGEMENT

The authors would like to express their gratitude to pediatric endocrine teams for allowing to complete this research

#### REFERENCES

- [1] Brizola, E. & Shapiro, J. R. (2015). Bisphosphonate treatment of children and adults with osteogenesis imperfecta: unanswered questions. *Calcified Tissue International*, 97, 101-103.
- [2] Macovei, S. & Mandache, R. Ş. (2014). Osteogenesis imperfecta and its consequences on the disabled children's capacity for effort and movement. *Procedia-Social and Behavioral Sciences*, 117, 67-73.
- [3] Forlino, A. & Marini, J. C. (2016), Osteogenesis imperfecta. *The Lancet*, 387(10028), 1657-1671.
- [4] Folkestad, L., Hald, J. D., Canudas-Romo, V., Gram, J., Hermann, A. P., Langdahl, B., Abrahamsen, B., & Brixen, K. (2016). Mortality and causes of death in patients with osteogenesis imperfecta: A register-based nationwide cohort study. *Journal of Bone and Mineral Research*, 31(12), 2159-2166.
- [5] Biggin, A. & Munns, C.F. (2014). Osteogenesis imperfecta: Diagnosis and treatment. *Curr Osteoporos Rep*, 12(3), 279-288.
- [6] Song, Y., Zhao, D., Li, L., Lv, F., Wang, O., Jiang, L., Xia, W., Xing, X., & Li, M. (2019). Health-related quality of life in children with osteogenesis imperfecta: A large-sample study. *Osteoporosis International*, 30, 461-468.
- [7] Hill, M., Lewis, C., Riddington, M., Crowe, B., DeVile, C., Götherström, C., & Chitty, L. (2019). Exploring the impact of osteogenesis imperfecta on families: A mixed-methods systematic review. *Disabil Health J*, 12(3), 340-349.
- [8] Parker, J. N. & M. Parker. (2007). *Osteogenesis Imperfecta-A Bibliography and Dictionary for Physicians, Patients, and Genome Researchers*. United States of America: ICON Group International.
- [9] Gajko-Galicka, A. (2002). Mutations in type I collagen genes resulting in osteogenesis imperfecta in humans. *Acta Biochimica Polonica*, 49(2), 433-441.
- [10] Cabral, W. A. & Marini, J. C. (2004). High proportion of mutant osteoblasts is compatible with normal skeletal function in mosaic carriers of osteogenesis imperfecta. *The American Journal of Human Genetics*, 74(4), 752-760.
- [11] Shapiro, J. R., Byers, P. H., Glorieux, F. H & Sponseller, P. D. (2014). *Osteogenesis Imperfecta. A Translational Approach to Brittle Bone Disease*. New York : Academic Press.
- [12] Palomo, T., Vilaça, T., & Lazaretti-Castro, M. (2017). Osteogenesis imperfecta: Diagnosis and treatment. *Current Opinion in Endocrinology & Diabetes and Obesity*, 24(6), 381-388.

- [13] Marr, C., Seaman, A., & Bishop, N. (2017), Managing the patient with osteogenesis imperfecta: A multidisciplinary approach. *Journal of multidisciplinary healthcare*, 145-155.
- [14] Sam, J. E. & Dharmalingam, M. (2017), Osteogenesis imperfecta. *Indian journal of endocrinology and metabolism*, 21(6), 903-908.
- [15] Marini, J.C.A., Forlino, Bächinger, H.P., Bishop N.J., Byers, P.H., De Paepe, A., Fassier, F., Fratzl-Zelman, N., Kozloff, K.M., Krakow, D., Montpetit, K and Semler, O. (2017). Osteogenesis imperfecta. *Nature reviews Disease primers*, 3(1), 1-19
- [16] Morello, R. & Esposito, P. W. (2012). Osteogenesis Imperfecta. *Osteogenesis*, Edited by Yunfeng Lin. Published by InTech, 223-52.
- [17] Arimbawa, I.M., Himawan, I.W., Rini, A.B.P.E.A., Marzuki, N.S., & Batubara, J.R. (2017). *Indonesian Pediatrician Association Clinical Practice Guide: Osteogenesis Imperfecta*. 1st Ed. Indonesian Pediatrician Association Publishing Agency.
- [18] Basel, D., & Steiner, R. D. (2009), Osteogenesis imperfecta: Recent findings shed new light on this once well-understood condition. *Genetics in medicine*, 11(6), 375-385.
- [19] Steiner, R. D. & Basel, D. (2019). COL1A1/2 osteogenesis imperfecta. *Genetics in Medicine*, 1-29.
- [20] Vanz A.P., Lee J.V.D.S., Pinheiro B., Zambrano M., Brizola E., Sicca N., et al. (2018) 'Health-related quality of life of children and adolescents with osteogenesis imperfecta : a cross-sectional study using PedsQLTM', *BMC Pediatrics*, pp. 1-6. doi:10.1186/s12887-018-1077-z.
- [21] Boyce, B. F., Zuscik, M. J., & Xing, L. (2018). *Biology of Bone and Cartilage*. *Genetics of Bone Biology and Skeletal Disease*. pp. 173-195. Cambridge, USA: Academic Press.
- [22] Harrington, J., Sochett, E., & Howard, A. (2014). Update on the evaluation and treatment of osteogenesis imperfecta. *Pediatric Clinics*, 61(6), 1243-1257.
- [23] Beary, J. F. & Chines, A. A. (2017). Osteogenesis imperfecta: Management and prognosis. Available at <http://www.uptodate.com/contents/osteogenesis-imperfecta-management-and-prognosis>. [16 September 2020]
- [24] Jobke, B., Milovanovic, P., Amling, M., & Busse, B. (2014). Bisphosphonate-osteoclasts: Changes in osteoclast morphology and function induced by antiresorptive nitrogen-containing bisphosphonate treatment in osteoporosis patients. *Bone*, 59, 37-43.
- [25] Eghbali-Fatourehchi, G. (2014). Bisphosphonate therapy in pediatric patients. *Journal of Diabetes & Metabolic Disorders*, 13(1), 1-11.
- [26] Baroncelli, G.I. and S.Bertelloni. (2014). The use of bisphosphonates in pediatrics. *Hormone research in paediatrics*, 82(5), 290-302.
- [27] Simm, P. J., Biggin, A., Zacharin, M.R., Rodda, C.P., Tham, E., A. Siafarikas, C., Jefferies, P.L., Hofman, D., Jensen, E., Woodhead H., Brown, J., Wheeler, J., Brookes, D., Lafferty, A., Munns, C.F and APEG Bone Mineral Working Group. (2018). Consensus guidelines on the use of bisphosphonate therapy in children and adolescents. *Journal of paediatrics and child health*, 54(3), 223-233.
- [28] Unit Kerja Koordinasi Endokrinologi IDAI. (2017). *Panduan Praktik Klinis Ikatan Dokter Anak Indonesia Osteogenesis Imperfecta*. Edisi pertama. Pp. 4-6. Jakarta: Badan Penerbit Ikatan Dokter Anak Indonesia.